



PATIENT PRESENTING CLINICAL SIGNS

- Pearl Drennan
- Didn't want to eat Tuesday, normally present for breakfast every morning but she was hiding instead
 - Not interested in treats
- SPECIES**
- Vomited once
 - Lethargic
- Feline
- Gave hairball medication in case it was a hairball
 - Abnormal PE/Chem/CBC/UA Results: PE: Hydration: 7-10% dehydrated

BREED RADIOGRAPHIC STUDY OF THE ABDOMEN

DSH Right /left lateral and ventrodorsal views totaling 3 images available for review.

RADIOGRAPHIC FINDINGS

SEX

FS The serosal detail is maintained throughout the peritoneal and retroperitoneal space.

AGE

3yr The liver is appropriate in position, size and presents uniform opacity.

INTERPRETED BY

Nele Eley (Ondreka),
DVM Dr. med. vet.,
DipECVDI

The stomach appears mostly empty. No radiopaque foreign material or abnormal soft tissue opacity is identifiable.

The small intestines are mildly turgid in appearance but not dilated or plicated. Bowel loops maintain normal caliber.

The colon contains gas and fluid with no evidence of displacement or obstruction.

HOSPITAL NAME

RADIOGRAPHIC DIAGNOSIS

Elizabeth Animal Hospital

- Suspect functional / dynamic ileus rather than mechanical obstruction
- Mild colon lymphadenopathy - may reflect reactive change
- No signs of acute obstructive lesion identified on survey radiographs

REFERRING VET

Leon Anderson DVM

INTERPRETATION OF FINDINGS & FURTHER RECOMMENDATIONS

INVOICE

24113

DATE

03/04/2026

The radiographs do not present direct signs of mechanical ileus or intestinal plication. Potential causes of functional ileus include GI inflammation, metabolic systemic disease, hepatic disease, renal disease, hypokalemia, pancreatitis, pain or stress, toxin exposure, as well as neurologic causes.

Radiographs cannot fully exclude obstructions, small linear foreign bodies or mucosal lesions. Clinical monitoring is advised. Further imaging such as abdominal ultrasound is recommended to evaluate bowel wall motility and lymph nodes in more detail especially if clinical signs persist.



PATIENT

Pearl Drennan

SPECIES

Feline

BREED

DSH

SEX

FS

AGE

3yr

INTERPRETED BY

Nele Eley (Ondreka),
DVM Dr. med. vet.,
DipECVDI

HOSPITAL NAME

Elizabeth Animal
Hospital

REFERRING VET

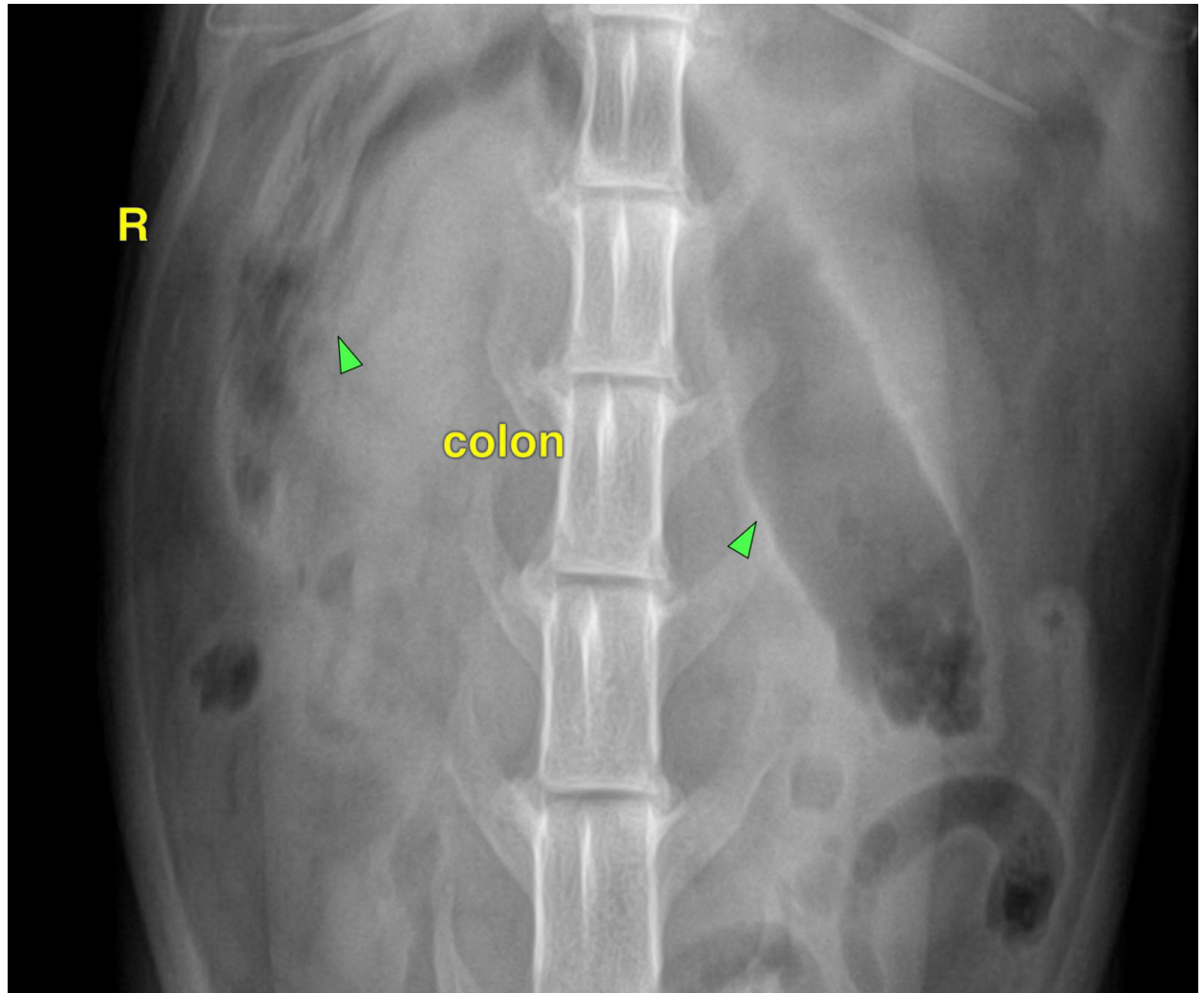
Leon Anderson DVM

INVOICE

24113

DATE

03/04/2026





PATIENT

Pearl Drennan

The information and recommendations provided are based on the images presented by the referring veterinarian. No evaluation can be communicated regarding pathology that was not visible in the image/video clips provided.

SPECIES

Feline

Thank you for this referral. If the clinical or image interpretation does not parallel your findings or if I can be of any further assistance please contact me.

BREED

DSH

Nele Eley (Ondreka), DVM, Dr. med. vet., DipECVDI
European Specialist in Veterinary Diagnostic Imaging, Cert. Radiology,
Senior lecturer University of Giessen/Germany, Veterinary Faculty, Department of Radiology.
info@sonopath.com

SEX

FS

AGE

3yr

INTERPRETED BY

Nele Eley (Ondreka),
DVM Dr. med. vet.,
DipECVDI

HOSPITAL NAME

Elizabeth Animal
Hospital

REFERRING VET

Leon Anderson DVM

INVOICE

24113

DATE

03/04/2026